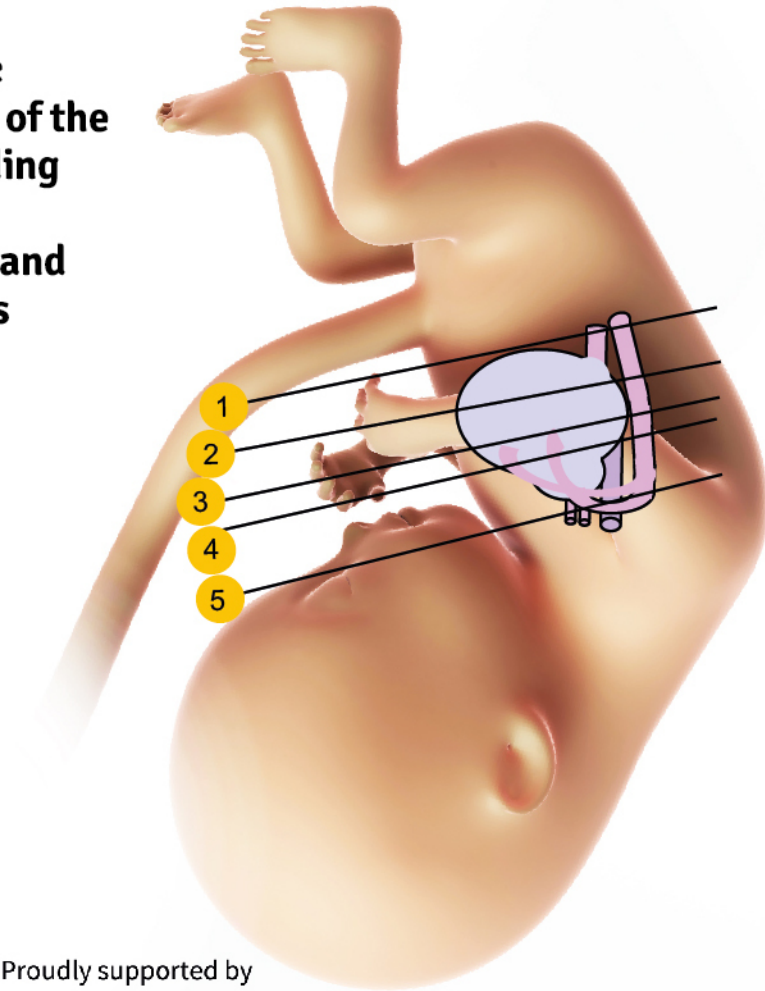
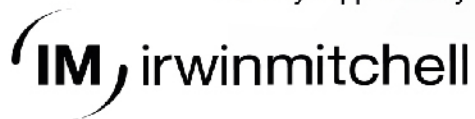

# Fetal Heart Screening in 5 Transverse Views

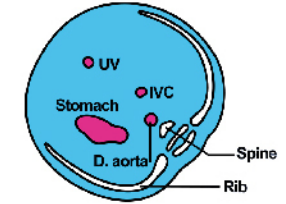
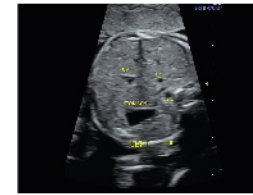A systematic examination of the heart, including orientation, connections and relationships



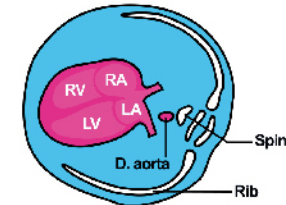
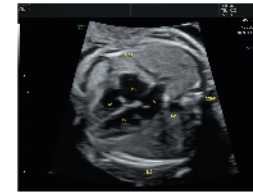
Proudly supported by



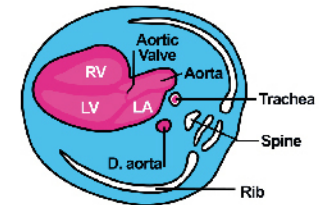
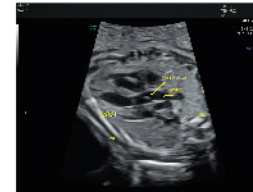
**1**  
Situs



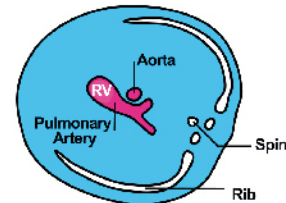
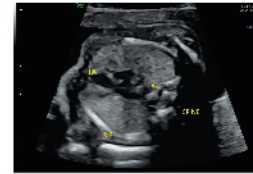**2**  
4-Ch



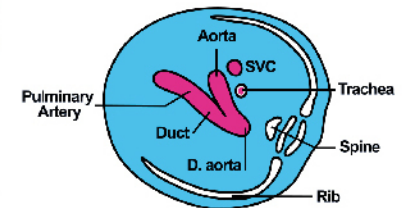
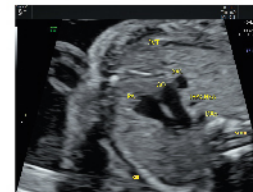**3**  
LVOT



**4**  
RVOT



**5**  
3 vessel & trachea (3VT)



Connect with us

